

Clinical Article

Treatment of Anterior Crossbite in the Primary Dentition With Esthetic Crowns: Report of 3 Cases

German Ramirez-Yañez, DDS, Pedro Spec, MDS, PhD¹

Abstract: Anterior crossbite is a sagittal malocclusion occurring in approximately 4 to 5% of children with primary dentition. Although self-correction may occur, treating an anterior crossbite as early as possible has been proposed to prevent problems in the transitional and permanent dentitions. The purpose of this paper is to present an optional restorative treatment used in 3 cases where an anterior crossbite was treated by restoring the primary maxillary incisors with esthetic pediatric strip crowns. In all 3 cases, the crossbite was successfully treated by using the proposed technique over 1 to 2 weeks. A 6-month follow-up showed that the occlusion stabilized into a sagittal normal relationship, permitting normal dentofacial growth and development to continue. The technique presented here can be added to the armamentarium of pediatric dentists and general practitioners to correct anterior crossbites diagnosed in the primary dentition. (*Pediatr Dent* 2011;33:339-42) Received December 23, 2009 | Last Revision April 25, 2010 | Accepted April 25, 2010

KEYWORDS: ANTERIOR CROSSBITE, MALOCCLUSION, EARLY TREATMENT

Anterior crossbite is a malocclusion that may be diagnosed in growing patients,¹ occurring in approximately 4 to 5% of the population in the primary or transitional dentition.^{2,3} One or more teeth may be involved, and it can be caused by either skeletal or dental problems, such as dental interferences appearing during the eruption of the primary incisors or canines.⁴ Thus, these crossbites can be defined as a functional problem developing at an early age, which might turn into a skeletal problem when the malocclusion remains through the transitional up to the permanent dentition.⁵

An anterior crossbite is easily identified in the primary dentition either by dentists or by parents who may seek early treatment during that developmental stage. Tsai reported that a smaller anterior cranial base, a retruded position of the maxilla, and a smaller interincisal angle are associated with anterior crossbite in children.⁶ Self-correction might occur in some patients during the transition from primary to permanent dentition.⁷ Some studies, however, have reported that, despite self-correction of the anterior crossbite, skeletal abnormalities remain.^{7,8} On the other hand, if self-correction does not occur, the anteroposterior relationship between the mandible and maxilla becomes worse with growth.⁹ Therefore, treating anterior crossbites should be advised when diagnosed in the primary dentition^{10,11} to prevent skeletal abnormalities in the adolescent or adult patient, which could lead to more severe problems such as mandibular overgrowth,⁸ mandibular asymmetries,¹² and/or temporomandibular dysfunction.¹³

Most of the proposed treatments for anterior crossbite have been designed to treat during the transitional dentition

(eg, quadhelix with extended anterior arms) and permanent dentition (eg, Hawley plate with anterior springs), but not the primary dentition. An alternative for treatment during the primary dentition is the chin-cap. It has been shown that using such an appliance for a long period improves the relationship between the mandible and maxilla by suppressing the mandible's antero-inferior growth.^{5,14} Nevertheless, some problems have been associated with the use of the chin-cap, such as rebound after ending treatment and excessive load applied to the temporomandibular joint.¹⁵⁻¹⁷

Removable appliances and fixed inclined planes have been proposed to treat this malocclusion at an early age. Compliance is always an issue when treating with these types of appliances, aside from the challenge a professional faces while delivering an appliance to a child in the primary dentition. Reversed stainless steel crowns have also been proposed to correct anterior crossbite.¹⁸ This technique, however, has some disadvantages, such as the difficulty of adapting a preformed crown to fit the incisors and the metallic appearance.¹⁹

A suitable technique using Planas' Direct Tracks (PDTs) has been reported to treat anterior and posterior crossbites in the primary dentition.^{10,20} PDTs are built up with composite on the primary molars, guiding the mandible to slide backward and permitting the tongue to deliver an appropriate force on the maxillary incisors. This brings the maxillary incisors into a normal position and positions the mandible backward in a better sagittal relation with the maxilla in a short period of time.^{10,20,21} Good patient cooperation, however, is necessary to build and adjust the PDTs on the primary molars.

The purpose of this paper is to describe a treatment alternative for anterior crossbites by buccally modifying the inclination of the primary maxillary incisors with esthetic pediatric strip crowns. This technique is proposed for patients who do not cooperate well when Planas Direct Tracks are built up.

¹Dr. Ramirez-Yañez is an assistant professor, Faculty of Dentistry, University of Manitoba, Winnipeg, Canada.

Correspond with Dr. Ramirez-Yañez at ramirezzy@cc.umanitoba.ca

Hence, crossbite can be treated in an easy manner without worrying about patient compliance and behavior. Following are 3 clinical cases presented where an anterior crossbite was corrected with pediatric composite crowns, regardless of whether or not the incisors had caries.

Case 1. A 4-year, 3-month-old aboriginal boy presented at Machray dental clinic in Winnipeg, Manitoba for his first dental visit. He was accompanied by his parents, who asked for restorative treatment due to caries on his 2 primary maxillary central incisors and expressed concern regarding the child's bite. The clinical exam revealed that the patient had an anterior crossbite with a negative overjet (-1 mm) and an overbite of 20%, associated with a Class III canine relationship and significant mesial step at the primary second molars (Figure 1a). When the mandible was manipulated to centric relation, it was possible to reach an edge-to-edge position with a centric relation/centric occlusion shift of 2 mm. The patient was cooperative during the exam, but because of his gag reflex, his behavior was not as good when bitewing radiographs were taken during the first appointment. The clinical and radio-

graphic exam revealed no problems other than incipient mesiobuccal caries on the primary maxillary central incisors and the anterior crossbite. Due to his strong gag reflex while taking radiographs, an alternative restorative treatment was sought for treating the crossbite instead of correcting it with PDTs.

A treatment plan was instituted to treat the carious lesions on the primary maxillary central incisors by restoring these teeth with an esthetic pediatric strip crown and changing the axial inclination of the crowns of these teeth, thereby creating an interference forcing the mandible to slide slightly backward (Figures 1b and 2). It also was necessary to place strip crowns on the primary maxillary lateral incisors to provide more support to the bite when closing the mouth immediately after treatment (Figure 1b). Treatment was performed with only topical anesthesia, reducing the incisors approximately 1 mm on the incisal, mesial, and distal aspects, and removing the carious tissue with a low-speed handpiece. Two weeks later, the mandible was sagittally positioned backward with a normal overjet, and the primary canines were in a Class I relationship with a slight mesial step at the primary second molars

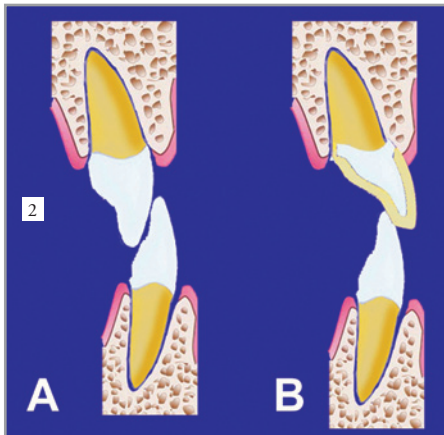
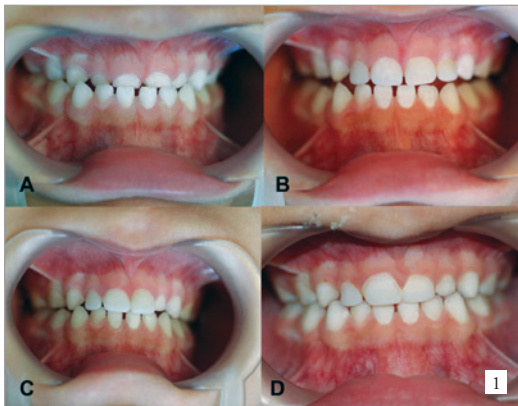

Figure 1. Photographs of clinical case no. 1 showing: (A) the anterior crossbite before treatment; (B) the primary maxillary incisors restored with pediatric strip crowns; (C) the crossbite corrected 1 week after treatment; and (D) stable occlusion of the primary dentition 6 months after treatment.

Figure 2. Diagram showing how to change the axial axis of the primary maxillary incisors to correct an anterior crossbite in the primary dentition. (A) Before treatment; (B) direction of the pediatric crown placement.

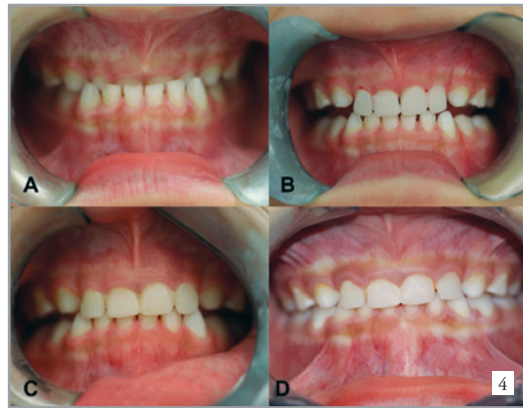
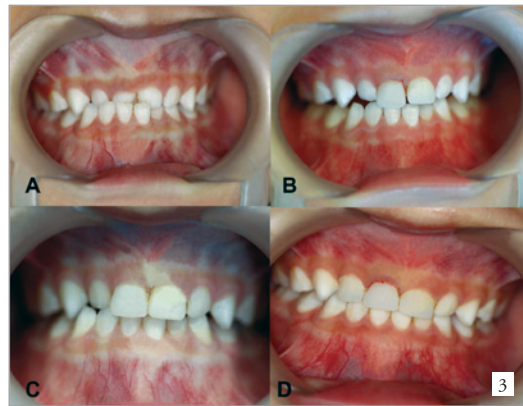
Figure 3. Photographs of clinical case no. 2 showing: (A) the anterior crossbite before treatment; (B) the primary maxillary central incisors restored with pediatric strip crowns; (C) the crossbite corrected 1 week after treatment; and (D) stable occlusion of the primary dentition, 6 months after treatment, with a pediatric crown also placed on the primary maxillary right lateral incisor.

Figure 4. Photographs of clinical case no. 3 showing: (A) the anterior crossbite before treatment; (B) the primary maxillary incisors restored with esthetic pediatric crowns; a transitory posterior open bite is produced by the treatment; (C) the crossbite corrected, 1 week after treatment, and the transitory open bite on the posterior segment closed; and (D) stable occlusion of the primary dentition 6 months after treatment.

(Figure 1c). A 6-month follow-up showed that the occlusion was stable with a normal relationship between the mandible and maxilla, and an ideal molar and canine relationship in the primary dentition was maintained (Figure 1d).

Case 2. A 4-year, 6-month-old Caucasian girl presented for a recall exam. The patient was previously seen in another dental clinic where the maxillary central incisors were treated because of caries, but no advice was given to the parents regarding the bite. The clinical exam revealed that the patient had an anterior crossbite involving the primary maxillary central incisors and the right lateral incisor, with a negative overjet (-1 mm) and an overbite of 40%, associated with a Class III canine relationship. The patient also had a significant mesial step at the primary second molars, being more severe on the left side, as the mandible shifted to the right side in maximum intercuspation (Figure 3a). Mandibular manipulation to position the bite in centric relation revealed that there was a centric relation-centric occlusion shift of approximately 1 mm.

The primary maxillary central incisors were restored similarly to Case 1, but not initially including the primary maxillary lateral incisors (Figure 3b). Similarly to the previous case, treatment was performed with topical anesthesia and the teeth were slightly reduced to give room for the strip crown and the composite. One week later, the mandible was positioned backward, but the primary maxillary right lateral incisor was in an edge-to-edge position (Figure 3c). Thus, an esthetic pediatric crown was also placed on that tooth, creating a normal overbite in that area and more stability to the bite. A 6-month follow-up showed that the occlusion was stable, with a normal relationship between the mandible and maxilla, and a normal molar and canine relationship in the primary dentition was also maintained (Figure 3d).

Case 3. A 3-year-, 5-month-old Asian girl presented for her first dental visit at the author's private practice in Winnipeg, Manitoba. Her parents were concerned about their child's bite and asked if it was possible to treat their daughter's bite at that age. The clinical exam revealed that the patient had an anterior crossbite, with a negative overjet (-2 mm) and an overbite of 90%, associated with a Class III canine relationship and significant mesial step at the primary second molars. (Figure 4a). The patient was cooperative during the exam, but her cooperation became poor when taking bite-wing radiographs, discouraging treating the anterior crossbite with PDTs. The clinical exam revealed no caries, but the primary maxillary incisors were worn to approximately half of the crown. The patient was able to bite in an edge-to-edge position shifting the mandible into centric occlusion (approximately 2 mm).

Thus, the 4 primary maxillary incisors were restored under topical anesthesia with esthetic pediatric strip crowns, as previously described in Cases 1 and 2. (Figure 4b). Immediately after treatment, only the incisors were contacting, and there was no occlusal contact on the posterior teeth including the canines. A week later, the mandible had moved backward, producing a normal overjet (Figure 4c). A 6-month follow-up showed that the occlusion was stable, with a normal relationship between the mandible and maxilla, and an ideal molar and canine relationship in the primary dentition was maintained (Figure 4d). The temporary posterior open bite observed immediately after the restorative treatment was no longer present. At this stage, there was a positive overjet with

a stable slight mesial step relationship; however, an increased overbite for her developmental stage was still present.

Discussion

Treating malocclusions in the primary dentition facilitates normal growth and development.^{20,22} Thus, pediatric and general dentists, as well as orthodontists, should be familiar with conditions known to interfere with growth and development of the dentofacial complex in growing patients, such as anterior crossbite.^{4,22} Treating a malocclusion early has been extensively proposed in the literature, but few techniques have been reported to treat crossbite in the primary dentition. This author has previously reported a technique, using PDTs, to treat both anterior and posterior crossbites.^{10,20} In the current paper, an optional treatment for anterior crossbite has been presented: restoring primary maxillary incisors with esthetic pediatric crowns.

The advantage of these techniques—using PDTs and restoring with pediatric crowns—is that they permit the dental professional to treat Class III malocclusions early without the concern of patient compliance associated with removable appliances²³ or putting the patient at risk of temporomandibular joint overloading, which may occur when using a chin-cap on a growing child.¹⁵⁻¹⁷ Furthermore, the technique described here does not require local anesthesia, as minimal crown preparation is performed on the enamel tissue and can be made with topical anesthesia.

In the 3 cases presented in this paper, an anterior crossbite was easily treated by restoring the primary maxillary incisors with esthetic pediatric crowns, which were placed in such a manner as to create interference when the teeth were occluded, moving the mandible backward. Although a posterior open bite and excessive force on the periodontium of the primary maxillary and mandibular incisors may be produced immediately after placing the crowns, these problems are transitory. The follow-up after 1 to 2 weeks showed that the mandible rapidly moves backward, closing the posterior open bite. Furthermore, a 6-month follow-up period in the 3 clinical cases presented here showed that the occlusion was stable, maintaining a normal sagittal relationship between the mandible and maxilla, as well as a normal canine and molar relationship in the primary dentition.

Thus, the reported results of the 3 clinical cases show that a 6-month follow-up period is reasonable after treating an anterior crossbite in the primary dentition to ensure that there is stability of the occlusion and improvement of the function in the new occlusion, as previously reported.²⁴ All 3 clinical cases reported here were followed during a 6-month period. Although these patients are still in the primary dentition, permanent incisors are expected to erupt in a normal relationship as the treatment repositioned the mandible backward, similarly to PDT treatments where there was no relapse when patients entered the transitional dentition.^{10,20} The maxillary permanent incisors, however, develop lingually to their primary incisors and might erupt into crossbite.

The technique proposed in this paper, tipping buccally the longitudinal axis of the crowns in the primary maxillary incisors to correct an anterior crossbite in the primary dentition—has advantages over other techniques proposed in the literature. First, it does not involve taking dental impressions and laboratory fabrication, which is necessary when treating with fixed or removable appliances. Second, this esthetic

treatment compared with stainless steel crowns is more acceptable to parents and children. Third, in patients with a sensitive gag reflex, maintaining an open mouth long enough to build the PDTs on the primary molars is a problem. Placing the esthetic crowns on the primary maxillary incisors is easier and does not stimulate that reflex. Last, enamel reduction is minimal and can, in most cases, be performed with topical and not infiltrative anesthesia.

Therefore, anterior crossbite is a malocclusion easily identified in the primary dentition; thus, its treatment should be considered as early as possible to permit the dentofacial complex to continue growing and developing into a physiological pattern. Early treatment of malocclusions, such as anterior crossbite, can minimize or eliminate future treatment by reducing the needs of more costly and complex orthodontic treatment.^{25,26} The 3 clinical cases presented here further confirm that the optimal timing to improve an abnormal skeletal relationship developing in growing patients with anterior crossbite is in the primary dentition.^{10,11,18,27}

Anterior crossbite is a malocclusion that may appear in the primary dentition, but which can be easily treated at that developmental stage. Restoring primary maxillary incisors with esthetic paediatric crowns and slightly changing the longitudinal axis of the crowns is a viable alternative for early anterior crossbite treatment. This is because it guides the mandible to posturing backward at the final occluding of the teeth, bringing the child's occlusion into a normal relationship and permitting dentofacial growth and development to continue into a more normal pattern.

References

- Keski-Nisula K, Lehto R, Lusa V, Keski-Nisula L, Varrela J. Occurrence of malocclusion and need of orthodontic treatment in early mixed dentition. *Am J Orthod Dentofacial Orthop* 2003;124:631-8.
- Ichiishi K, Kitamura M, Masumori M, Kikuchi M, Dohi M, Akasaka M. Recent situation concerning dental disease and nutritive condition of young children. *Shoni Shikagaku Zasshi* 1997;35:821-8.
- Grando G, Young AAA, Vedovello Filho M, Vedovello SAS, Ramirez-Yañez GO. Prevalence of malocclusions in a young Brazilian population. *Int J Orthod* 2008;19:13-6.
- Ngan P, Hu AM, Fields HW Jr. Treatment of Class III problems begins with differential diagnosis of anterior crossbites. *Pediatr Dent* 1997;19:386-95.
- Tsai HH. Components of anterior crossbite in the primary dentition. *J Dent Child* 2001;68:27-32.
- Nagahara K, Suzuki T, Nakamura S. Longitudinal changes in the skeletal pattern of deciduous anterior crossbite. *Angle Orthod* 1997;67:439-46.
- Nagahara K, Murata S, Nakamura S, Tsuchiya T. Prediction of permanent dentition in deciduous crossbite. *Angle Orthod* 2001;71:390-5.
- Sawa S. Roentgeno-cephalometric study on the dentocraniofacial growth of the individuals with reversed occlusion. *Nippon Kyosei Shika Gakkai Zasshi* 1978;37:237-68.
- Baccetti T, Tollaro I. A retrospective comparison of functional appliance treatment of Class III malocclusions in the deciduous and mixed dentitions. *Eur J Orthod* 1998;20:309-17.
- Ramirez-Yañez GO. Planas' Direct Tracks as a useful method to correct cross-bite in an early age: Description of the technique and a case report. *J Clin Orthod* 2003;37:294-8.
- Lam PH, Sadowsky C, Omerza F. Mandibular asymmetry and condylar position in children with unilateral posterior crossbite. *Am J Orthod Dentofacial Orthop* 1999;115:569-75.
- Alamoudi N. The correlation between occlusal characteristics and temporomandibular dysfunction in Saudi Arabian children. *J Clin Pediatr Dent* 2000;24:229-36.
- Thilander B. Chin-cap treatment for Angle Class III malocclusion: A longitudinal study. *Trans Eur Orthod Soc* 1965;41:311-27.
- Lu YC, Tanne K, Sakuda M. The effects of orthopaedic treatment with chin cap on craniofacial growth in adolescent Class III patients. *J Osaka Univ Dent* 1991;316:85-94.
- Mitani H, Sakamoto T. Chin cap force to a growing mandible: Long-term clinical report. *Angle Orthod* 1984;54:93-122.
- Agronin KJ, Kokich VG. Displacement of the glenoid fossa: A cephalometric evaluation of growth during treatment. *Am J Orthod Dentofacial Orthop* 1987;91:42-8.
- Imai T, Watanabe F, Nakamura S. A clinical study on the prevalence of temporomandibular joint dysfunction in orthodontic patients. *Jpn Dent J* 1990;27:97-9.
- Sexton T, Croll TP. Anterior crossbite correction in the primary dentition using reversed stainless steel crowns. *J Dent Child* 1983;9:84-94.
- Croll TP. Correction of anterior tooth crossbite with bonded resin-composite slopes. *Quintessence Int* 1996;27:7-10.
- Ramirez-Yañez GO. Early Treatment of Malocclusions: Prevention and Interception in Primary Dentition. Ontario, Canada: Northern Lights Ed; 2009:111-22.
- Planas P. Rehabilitacion Neuro-oclusal. Madrid, Spain: Salvat Ed; 2004:185-233.
- Ngan P, Fields H. Orthodontic diagnosis and treatment planning in the primary dentition. *J Dent Child* 1995;62:25-33.
- Gross AM, Samson G, Dlerkes M. Patient cooperation in treatment with removable appliances: A model of patient noncompliance with treatment implications. *Am J Orthod* 1985;87:392-7.
- Yawaka Y, Hronaka S, Akiyama A, Matzuduka I, Takasaki C, Oguchi H. Changes in occlusal contact area and average bite pressure during treatment of anterior crossbite in primary dentition. *J Clin Pediatr Dent* 2003;28:75-9.
- Karaiskos N, Wiltshire WA, Odlum O, Brothwell D, Hassard TH. Preventive and interceptive orthodontic treatment needs of an inner-city group of 6- and 9-year-old Canadian children. *J Can Dent Assoc* 2005;71:649.
- Bernas A, Bantong D, Short L. Effectiveness of phase I orthodontic treatment in an undergraduate teaching clinic. *J Dent Educ* 2007;71:1179-86.
- Tschill P, Bacon W, Sonko A. Malocclusion in the deciduous dentition of Caucasian children. *Eur J Orthod* 1997;19:361-7.